

A Study on Antibacterial, Antioxidant, and Hepatoprotective Efficacy of *Elephantopus scaber* L.

(Suatu Kajian Keberkesanan Antibakteria, Antioksidan dan Hepatopelindung *Elephantopus scaber* L.)

NGUYEN TRONG HONG PHUC* & PHAN THANH DAT

School of Education, Can Tho University, Can Tho City, Vietnam

Received: 19 April 2022/Accepted: 9 August 2022

ABSTRACT

Elephantopus scaber is an herb widely used in folk remedies in Vietnam, especially in the treatment of liver disease. However, scientific studies evaluating the activity and ability to treat the disease in a scientific way are still very limited. This study evaluated the antibacterial, antioxidant, acute toxicity and hepatoprotective efficacy of *E. scaber* extracts. The extracts restricted the growth of 6 types of bacteria, being particularly most effective against *E. coli*. It was found that the *E. scaber* leaves extract was more efficient than root, stem, flower, and whole plant extracts. DPPH assay showed that the flower extract had the highest antioxidant activity ($EC_{50} = 60.29 \mu\text{g/mL}$). The *E. scaber* extracts ($>5000 \text{ mg/kg}$) also did not cause acute toxicity in mice. Additionally, the extracts effectively protected and recovered mice liver cells damaged by CCl_4 . The reduction of mice liver enzyme levels (AST and ALT) was similar between the extracts and silymarin. This hepatoprotective efficiency was also illustrated by the morphology and histology of the mice liver cells. The extracts healed mice liver cells by recovering the cell diameter, reducing inflammation swelling and increasing Hb concentration.

Keywords: Acute toxicity; antibacterial; antioxidant; *Elephantopus scaber*; hepatoprotective

ABSTRAK

Elephantopus scaber ialah herba yang digunakan secara meluas dalam ubat-ubatan di Vietnam, terutamanya dalam rawatan penyakit hati. Walau bagaimanapun, kajian saintifik untuk menilai aktiviti dan keupayaan untuk merawat penyakit secara saintifik masih sangat terhad. Kajian ini menilai keberkesanan antibakteria, antioksidan, ketoksikan akut dan hepatopelindung ekstrak *E. scaber*. Ekstrak ini merencat pertumbuhan 6 jenis bakteria, paling berkesan terutamanya terhadap *E. coli*. Didapati bahawa ekstrak daun *E. scaber* lebih cekap daripada ekstrak akar, batang, bunga dan keseluruhan tumbuhan. Ujian DPPH menunjukkan bahawa ekstrak bunga mempunyai aktiviti antioksidan yang paling tinggi ($EC_{50} = 60.29 \mu\text{g/mL}$). Ekstrak *E. scaber* ($>5000 \text{ mg/kg}$) juga tidak menyebabkan ketoksikan akut pada tikus. Selain itu, ekstrak berkesan melindungi dan memulihkan sel hati tikus yang rosak oleh CCl_4 . Pengurangan tahap enzim hati tikus (AST dan ALT) adalah serupa antara ekstrak dan silimarin. Kecekapan hepatopelindung ini juga digambarkan oleh morfologi dan histologi sel hati tikus. Ekstrak itu menyembuhkan sel hati tikus dengan memulihkan diameter sel, mengurangkan bengkak keradangan dan meningkatkan kepekatan Hb.

Kata kunci: Antibakteria; antioksidan; *Elephantopus scaber*; hepatopelindung; ketoksikan akut

INTRODUCTION

The *Elephantopus scaber* (Asteraceae family) is widely distributed in Vietnam, from the Ha Giang province in the northeast, to different provinces in the Mekong Delta, especially in the An Giang province (Le 2007; Pham 2003). This plant species possesses numerous bioactive

compounds, such as phenolic compounds, flavonoids, terpenoids, sesquiterpene lactones, lupeol, lupeol acetate, ursolic acid, stigmasterol steroids, glycosides, alkaloids, quinones, carbohydrates, saponins, and tannins (Das & Bandyopadhyay 2017; Jamali 2017).

These compounds contribute to *E. scaber*'s biological activities, such as anticancer, antimicrobial, antidiabetic, antioxidant, anti-inflammatory, hepatoprotective, anti-parasitic, anti-HIV, anti-asthmatic, improving memory power, nephroprotective, wound healing, and anti-pest activity (Mandal et al. 2019). Therefore, this plant has been used in traditional remedies as an antipyretic, diuretic, and anti-cough agent; as an emollient; and for the treatment of bronchitis, wound healing, gastropathy, nephritis, edema, arthritis, diarrhea, dysentery, blood vomiting, especially hepatitis and cirrhosis (Bich et al. 2006; La et al. 2005; Vo 2012).

Although *E. scaber* is widely used in Vietnamese traditional medicine, to the best of our knowledge, there is a lack of published scientific studies on its biological activities, such as antibacterial, antioxidant, and hepatic protective efficacy. Moreover, although previous studies have shown that secondary compounds in *E. scaber* have antibacterial and antioxidant activities, they have not shown that extracts from *E. scaber* have medicinal properties. This is of particular importance since people often use the whole herb to make traditional medicine. Therefore, this study was conducted using both *in vitro* and *in vivo* methods to assess the antibacterial and antioxidant capacity of *E. scaber* extracts, and to evaluate its potential for the clinical treatment of liver disease in humans by using the mouse model.

MATERIALS AND METHODS

PLANT MATERIAL

For the experiments, *E. scaber* (12 kg) was obtained from the To mountain in the An Giang Province, Vietnam. It was morphologically classified with reference to An Illustrated Flora of Vietnam² and Flora of Vietnam – Asteraceae Dumort (Le 2007).

PREPARATION OF AQUEOUS EXTRACT

E. scaber and its parts (roots, stems, leaves, and flowers) were collected and dried using a sample drying cabinet set at 50 °C. The dried *E. scaber* parts were then ground into fine powder. Twenty-five grams of the plant powder was then macerated in 750 mL of water and boiled (90 – 100 °C) for 30 minutes in a conical flask. The extract was filtered using 15-20 µm pore size filter paper, and then the filtrate was evaporated using a rotary evaporator (RV 10 digital V-C, IKA, Germany) (Al-Manhel & Kareem Niamah 2012).

EXPERIMENTAL ANIMALS

The study was conducted in accordance with the policy for experimental and clinical studies (Assessment No. AWA2020-02/KSP). Fifty-eight male Swiss mice *Mus musculus* (30-35 g) obtained from the Pasteur Institute in Ho Chi Minh City, Vietnam were used for the experiments. These mice were fed twice per day with a standard diet (containing 38% crude protein) and were acclimatized to experimental conditions (27-32 °C, humidity 65-80%, and 12:12 dark/light cycle) for 7 days before the study. All of the mice were randomly distributed into 10 groups (4 groups for the toxicity test and 6 groups for the hepatoprotective test).

ANTIBACTERIAL ACTIVITY

The antibacterial activity of the *E. scaber* extracts was determined according to Parkavi et al. (2012). Six strains of bacteria that included both Gram negative and positive species were used in the experiment, which were *Bacillus subtilis* (ATCC23857TM), *Bacillus cereus* (ATCC14579TM), *Escherichia coli* (ATCC25922TM), *Salmonella* sp., *Staphylococcus aureus* (ATCC25923TM), and *Listeria innocua*. One-hundred (100) µL of each bacterial species (10⁶ CFU/mL) were spread evenly over the surface of LB agar plates. On each plate, seven (7) wells were made with a sterile metallic borer (6 mm in diameter). Following the Zaidan et al. (2005)' method, 50 µL of distilled water that served as the negative control, ampicillin (0.001 mg/mL) as the positive control, and *E. scaber* extracts at different concentrations (10, 50, 100, 150, and 200 mg/mL) were added into each well. These plates were then incubated at 37 °C for 24 hours. At the end of the incubation period, sterile zone was determined by measuring the diameter and then subtracting 6 mm of well diameter. The tests were triplicated.

ANTIOXIDANT ACTIVITIES BY DPPH ANTIOXIDANT ASSAY

The capability of *E. scaber* roots, stems, leaves, flowers, and the whole plant extracts to scavenge the 2,2-diphenyl-1-picrylhydrazyl (DPPH) radical was determined according to the method of Aquino et al. (2001) and Zarezade et al. (2018) with some modifications. The reaction mixture consisted of 80 µL of methanol DPPH solution (1000 µg/mL) and 1920 µL of *E. scaber* extract at different concentrations (10, 50, 100, 150, and 200 mg/mL). The absorbance capacity of each treatment was

determined at 515 nm after a 20 minutes incubation at room temperature. Tocopherol (vitamin E) was used as the positive control. EC_{50} was graphically determined from the graph by plotting the inhibition percentage against the extract concentration.

The free radical scavenging activity (%) was calculated as follows:

Free radical scavenging activity (%)

$$= \frac{A_{\text{control}} - A_{\text{sample}}}{A_{\text{control}}} \times 100$$

ACUTE TOXICITY STUDY OF *E. scaber* AQUEOUS EXTRACT

The *E. scaber* whole plant aqueous extract at doses of 0 mg/kg (water), 300 mg/kg, 2000 mg/kg, and 5000 mg/kg were administered orally to four groups of mice, that comprised of 10 male mice (30-35 g) in each group, following the guidelines stipulated by the Organization for Economic Cooperation and Development – Oral Guideline 420 (OECD 2002). The mice were given the extract orally once daily with a maximum volume of 10 mL/kg of body weight. The mice were then observed for behavioral changes for 72 hours.

HEPATOPROTECTIVE ASSAY

Hepatoprotective activity was determined based on the methods of Kang and Koppula (2014) and Xia et al. (2019). A total of 18 mice was equally divided into six groups of three mice each. Group I served as the control and received only the distilled water (1 mL/kg/day). Group II served as the negative control and was treated with 1 mL/kg carbon tetrachloride (CCl_4) (1:4 of CCl_4 in olive oil) once daily. Group III served as the positive control and the mice in this group received 1 mL/kg CCl_4 1 mL/kg (1:4 ratio of CCl_4 in olive oil) and silymarin (17 mg/kg). Group IV, V, and VI received 1 mL/kg CCl_4 (1:4 ratio of CCl_4 in olive oil) and were treated with the *E. scaber* whole plant extract (200 mg/kg, 400 mg/kg, and 800 mg/kg). All of these treatments were orally administered for 14 days. At the end of the experiment, the animals were humanely sacrificed by stretching the spine after being anesthetized with diethyl ether. Blood and liver tissue samples were then collected. The livers were fixed in 10% neutral formalin for histological examination. Blood was collected from each animal for red blood cell count (RBC), hemoglobin concentration (Hb), serum alanine aminotransferase (ALT), and

aspartate aminotransferase (AST) activity to examine the liver function. Liver samples were preserved in 10% buffered formalin and dehydrated in ascending grades of ethanol and cleared in xylene. The specimens were then embedded in paraffin and cut into sections with 5 μ m thickness. The sections were stained with hematoxylin and eosin Y (H&E). The degree of necrosis, hepatocyte size, and hepatocyte nuclear size were observed under a CX23 light microscope (Olympus, Japan) with a digital camera using the OptixCam Toupview software (Microscope, USA). Hematological parameters including RBC and Hb were determined using a CELL-DYN Ruby Automated Hematology Analyzer (Abbott, USA). AST and ALT concentrations were determined using the Cobas clinical chemistry automatic analyzer (La Roche Ltd., Japan).

STATISTICAL ANALYSIS

Experimental data were processed and graphed using Microsoft Excel software (Ver.2019; Microsoft Inn., USA). Differences among means was determined using IBM SPSS 22 (SPSS Inn., USA) via ANOVA and Duncan post-hoc at 95% confidence.

RESULTS AND DISCUSSION

ANTIBACTERIAL ACTIVITY OF *E. scaber*

The *E. scaber* leaf extract showed the highest activity against all tested pathogen strains, followed by the flower extract, and whole plant extract. Meanwhile, the root and stem extracts consistently showed the lowest antibacterial activity (Figure 1).

Table 1 compares the antibacterial activity of all *E. scaber* extracts at the highest concentration (200 mg/mL). It was found that all of the extracts exhibited the highest antibacterial activity against *E. coli* ($p < 0.05$) at this concentration. *E. scaber* extracts also inhibited the growth of *L. innocua* and *Salmonella* sp. which were not reported in previous studies (Ahmed Chyad Ali et al. 2018; Anitha, Antonisamy & Jeeva 2012; Aslam et al. 2016; Jamali 2017; Jenny et al. 2012; Pandian, Banu & Kumar 2006).

Virulent strains of *E. coli* can cause gastroenteritis, urinary tract infections, neonatal meningitis, haemolytic uremic syndrome, peritonitis, mastitis, and septicaemia (Anitha, Antonisamy & Jeeva 2012). In this study, *E. coli* was inhibited by the *E. scaber* extracts, indicating its promising use in the treatment of urinary tract infections

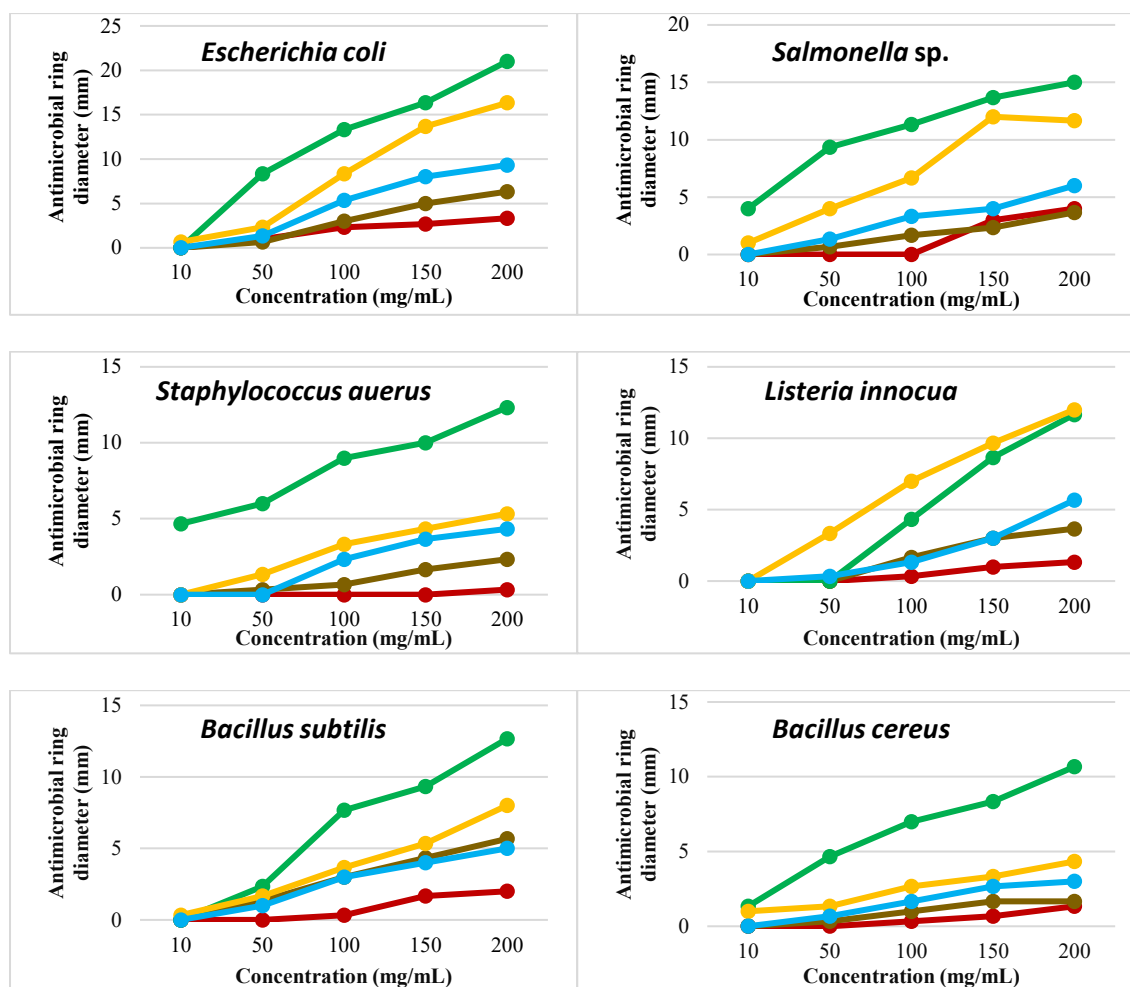


FIGURE 1. Inhibition zone of *E. scaber* extracts (mm) — Whole plant; — Flower; — Leaf; — Stem; — Root

TABLE 1. Inhibition zone of *E. scaber* at 200 mg/mL

<i>E. scaber</i> extract	Antibacterial ring diameter (mm)					
	<i>E. coli</i>	<i>Sal. sp</i>	<i>S. aureus</i>	<i>L. innocua</i>	<i>B. subtilis</i>	<i>B. cereus</i>
Root	3.33±0.58 ^A	4.00±0.00 ^A	0.33±0.58 ^A	1.33±0.58 ^A	2.00±0.00 ^A	1.33±0.58 ^A
Stem	6.33±0.58 ^B	3.67±0.58 ^A	2.33±1.15 ^{AB}	3.67±1.15 ^B	5.67±0.58 ^B	1.67±0.58 ^{AB}
Leaf	21.00±1.00 ^E	15.00±2.00 ^D	12.33±1.15 ^D	11.67±0.58 ^C	12.67±1.53 ^D	10.67±1.15 ^D
Flower	16.33±1.53 ^D	11.67±2.52 ^C	5.33±0.58 ^C	12.00±1.00 ^C	8.00±2.65 ^C	4.33±1.15 ^C
Whole plant	9.33±0.58 ^C	6.00±1.73 ^B	4.33±0.58 ^{BC}	5.67±0.58 ^B	5.00±1.00 ^B	3.00±0.00 ^{BC}

Mean ± SD with the same letter in the column are not significantly different (Duncan, $P > 0.05$)

and neonatal meningitis. The *E. scaber* extracts also displayed inhibitory activity against *B. cereus*, which can cause nausea, vomiting, and diarrhea (Carlin & Nguyen-The 2013; Pexara & Govaris 2010) when present in high numbers. This result supports the folk-medicinal use of this plant in treating these symptoms (Ho 2003; La et al. 2005; Vo 2012).

ANTIOXIDANT ACTIVITY OF *E. scaber* EXTRACT

The antioxidant properties of various extracts from many plants have been of great interest in academia, food, cosmetic, and pharmaceutical industries since they can be used as natural additives. Moreover, there is a growing tendency to replace synthetic antioxidants with

naturally-derived ones (Manssouri, Znini & Majidi 2020). Antioxidants are able to reduce DPPH radicals, causing a decrease in their absorbance at 515 nm. This DPPH radical scavenging ability may be due to the antioxidants' ability to donate hydrogen (Nithya & Madhavi 2017). DPPH is a stable free radical that accepts an electron or hydrogen to form a stable diamagnetic molecule. DPPH, which is purple in methanol, will turn into a yellow solution in the presence of a free radical scavenging agent (Molyneux 2004).

In this study, the scavenging effect of the *E. scaber* extract linearly increased when its concentration rose. Thus, linear regression equations and EC_{50} values were calculated from the results of the *E. scaber* extracts and compared with that of vitamin E (Table 2).

TABLE 2. EC_{50} value of *E. scaber* extract

<i>E. scaber</i> extract	Linear regression equation	R ²	EC_{50} (µg/mL)
Root	$y = 0.0742x - 2.5786$	0.9309	708.61
Stem	$y = 0.2476x - 4.5242$	0.9443	220.21
Leaf	$y = 0.3775x - 0.1904$	0.9759	132.95
Flower	$y = 0.8953x - 3.9778$	0.9555	60.29
Whole plant	$y = 0.5132x - 3.6688$	0.9657	104.62
Vitamin E	$y = 4.3883x - 4.1490$	0.9695	12.34

According to the results obtained, none of the *E. scaber* extracts showed antioxidant activity as strong as vitamin E. The flower extract had the highest antioxidant activity in comparison with the other *E. scaber* extracts ($EC_{50} = 60.29$ µg/mL). The whole plant extract was ranked second ($EC_{50} = 104.62$ µg/mL), followed by leaf and stem extracts at 132.95 µg/mL and 220.21 µg/mL, respectively. Although the antioxidant activity of *E. scaber* was lower than vitamin E, it could potentially be used in the liver healing process. This is because this process is accelerated by antioxidant activity with almost negligible side effects, thus herbal medicines have been used for this purpose (Chaudhari & Mahajan 2016).

ACUTE TOXICITY OF *E. scaber* EXTRACT

Although medicinal plants contain elements that are essential for humans, these may become toxic when present at high concentrations (Brown 2017b, 2017a)

hepatotoxic herbs and dietary supplements based on PubMed case reports exists in a summarized tabular form. Methods Documented case reports of herbs or dietary supplements (DS; includes herbs. One of the important steps to improve the overall safety and quality of medicinal plants and herbal products is to determine their acute toxicity (Street et al. 2008). In this study, the acute oral toxicity assay was carried out based on the OECD Guideline 420 (OECD 2002). The results showed that all of the treated mice could tolerate and remained alive after 72 hours of treatment with *E. scaber* at 300, 2000, and 5000 mg/kg without any abnormalities. Therefore, the LD_{50} value of the *E. scaber* extract was unable to be calculated and is considered nontoxic in oral consumption up to 5000 mg/kg in mice.

No statistically significant differences in AST, ALT, RBC, and Hb were observed between the treated groups and the control (Table 3). The Hb concentrations and

RBC numbers showed that the extract had no potential in inducing anemia. Also, the AST and ALT levels showed that normal functioning of the hepatocellular membrane. A dysfunction of the hepatocellular membrane or general liver damage will result in increased levels of AST and ALT (Saha et al. 2011). Thus,

the normal values of AST, ALT, RBC, and Hb in this test showed a good safety profile of the *E. scaber* extract on liver function.

The livers, kidneys, and spleen morphologies of the treated mice were indistinguishable from the untreated control (Figure 2). The stained and sliced liver was

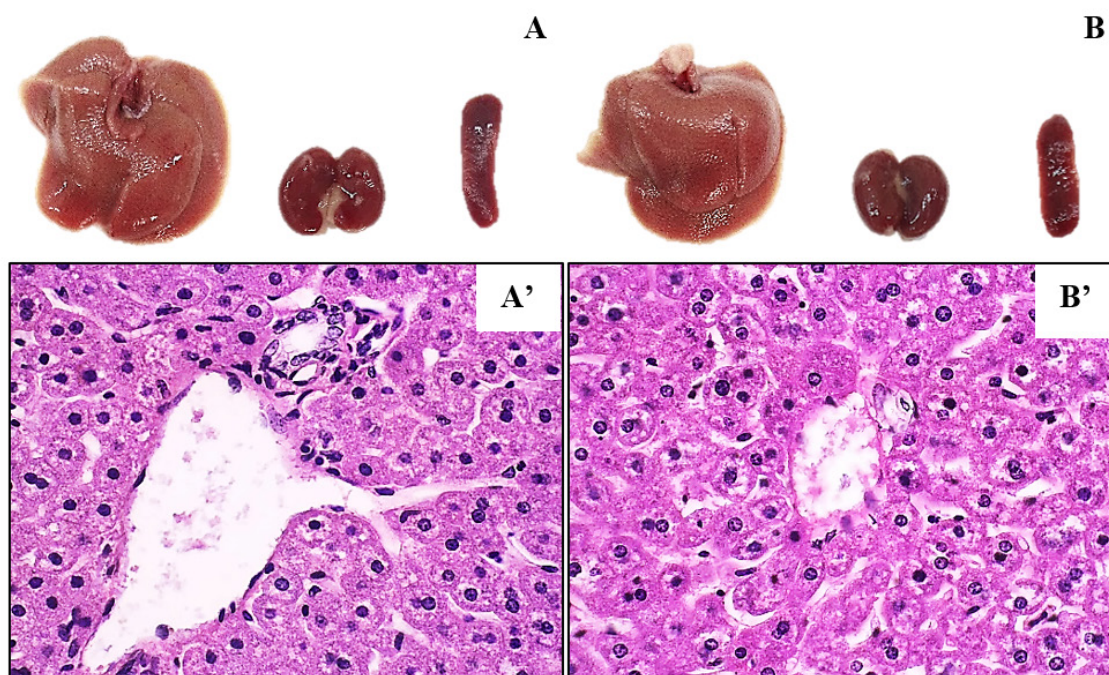


FIGURE 2. The liver, kidney, spleen morphologies, and liver histopathology. A: distilled water group; A': the liver histopathology of the distilled water group; B: 5000 mg/kg group; B': the liver histopathology of the 5000 mg/kg group

exhibited normal cell morphology after 72 hours of treatment at 5000 mg/kg. No necrosis or fatty infiltration were observed, indicating the good safety profile of the extract. In conclusion, even at the highest concentration of 5000 mg/kg, the *E. scaber* extract did not lead to acute

toxicity in mice.

TABLE 3. AST, ALT, RBC, and Hb values of acute toxicity test groups

Group	AST (U/L)	ALT (U/L)	RBC (mil/mm ³)	Hb (g/100 mL)
Distilled water	122.67±44.30 ^a	36.00±9.17 ^a	6.56±0.13 ^a	12.20±1.68 ^a
300 mg/kg	107.00±22.11 ^a	43.67±9.87 ^a	7.15±0.26 ^a	17.89±1.63 ^b
2000 mg/kg	108.00±32.05 ^a	42.33±3.79 ^a	6.16±0.37 ^a	13.13±0.37 ^a
5000 mg/kg	109.33±20.43 ^a	36.33±5.51 ^a	6.46±0.98 ^a	14.23±0.69 ^a

Means ± SD in a column having the same letters are not significantly different (Duncan, $p > 0.05$)

AST and ALT

CCl₄ is commonly used as a standard hepatotoxin for in vivo studies (Rajesh & Latha 2001). The hepatotoxic mechanism is via transformation of CCl₄ into a highly reactive trichloromethyl (CCl₃[·]) radical by cytochrome P450 in the liver endoplasmic reticulum. CCl₃[·] then reacts readily with O₂ to form the peroxy-trichloromethyl (CCl₃OO[·]) radicals. These free radicals initiate lipid peroxidation, thereby disrupting the structure and function of cell membranes (Abdel-Ghany et al. 2016).

When hepatic dysfunction takes place, AST and ALT are leaked from the cytoplasm into the bloodstream. Therefore, by measuring these two enzymes, liver cell damage could be assessed (Rajesh & Latha 2001). The current study showed that the CCl₄ treated group had the highest AST and ALT activities. Specifically, the levels of AST (1160.00±497.80 U/L) and ALT (1805.00±1303.90 U/L) were significantly higher ($p < 0.05$) in comparison to the distilled water group (AST: 51.00±2.65 U/L; ALT: 31.67±6.66 U/L) (Table 4).

TABLE 4. Biochemical parameters and therapeutic efficacy of extracts

Group	AST (U/L)	AST-RP (%)	ALT (U/L)	ALT-RP (%)
Distilled water	51.00±2.65 ^a	100.00±0.00 ^c	31.67±6.66 ^a	100.00±0.00 ^d
CCl ₄	1160.00±497.80 ^b	0.00±0.00 ^a	1805.00±1303.90 ^b	0.00±0.00 ^a
Silymarin	399.67±118.50 ^a	63.40±12.62 ^b	618.00±174.25 ^a	67.90±11.54 ^{bc}
200 mg/kg	395.67±317.30 ^a	75.28±20.31 ^{bc}	493.00±344.07 ^a	81.0± 9.72 ^c
400 mg/kg	521.00±288.50 ^a	67.86±19.63 ^b	763.00±558.61 ^a	59.43±1.94 ^b
800 mg/kg	230.33±208.35 ^a	85.22±13.93 ^{bc}	405.33±405.18 ^a	78.62±12.30 ^c

Means ± SD in columns having the same letter are not significantly different (Duncan, $p > 0.05$). AST-RP: reduced performance of AST; ALT-RP: reduced performance of ALT

On the other hand, silymarin, whose most active flavonoid component is silybin, has a powerful protective effect against CCl₄ hepatotoxicity (Abdel-Ghany et al. 2016). In the present study, the silymarin treated positive control group, and all *E. scaber* extracts (200 mg/kg, 400 mg/kg and 800 mg/kg) treated groups showed significant reduction in AST and ALT levels compared to the CCl₄ group ($p < 0.05$) (Table 4). The AST and ALT reduction efficiency of both silymarin and the *E. scaber* extracts was similar, at 63% to 85% ($p > 0.05$). This indicates the hepatoprotective potential of the *E. scaber* extract against CCl₄.

RED BLOOD CELL AND HEMOGLOBIN

In this study, the RBC and Hb of experimental mice treated with *E. scaber* extract were counted to investigate its hematopoietic ability (Figure 4). The results showed that the distilled water control group had the highest number of RBC (7.91±1.11 million/mm³), whereas the CCl₄, silymarin, and *E. scaber* extract treatment groups

had similar numbers of RBC ($p > 0.05$). This indicates that silymarin and *E. scaber* extracts were unable to reduce the destruction of erythrocytes by CCl₄ in this study (Figure 3(A)).

The CCl₄ group had the lowest Hb concentration (11.77±1.62 g/100 mL). Meanwhile, the Hb concentrations in the silymarin and *E. scaber* extract treatment groups increased from 13.29±1.96 g/100 mL to 15.02±1.55 g/100 mL, which were similar to the distilled water group 14.19±0.82 g/100 mL ($p < 0.05$). Therefore, the *E. scaber* extracts increased the Hb concentration in mice treated with CCl₄ (Figure 3(B)).

DIAMETER OF HEPATOCYTES

The diameter of hepatocytes of 30 randomly selected cells from around the central vein at the edge of the liver was measured. The results showed that the histology of the hepatocytes was different among the treatments ($p < 0.05$).

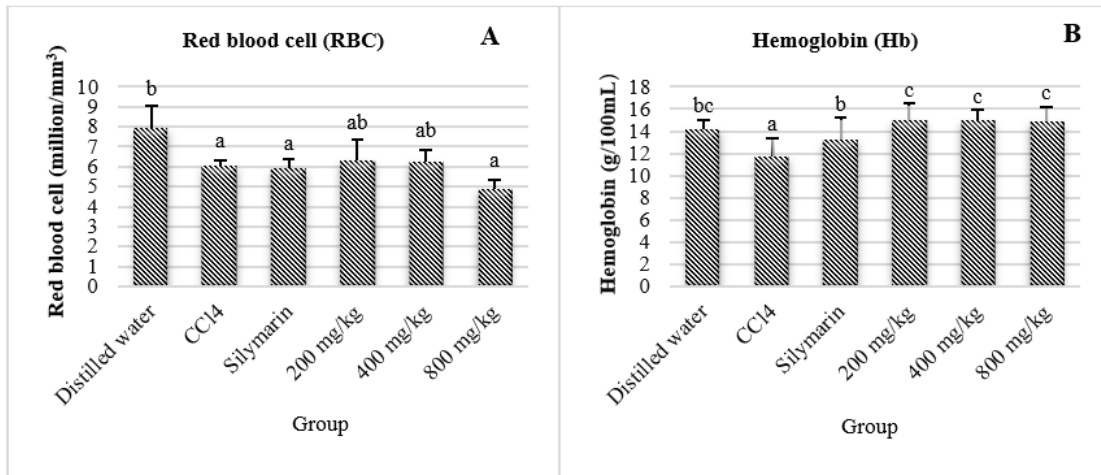


FIGURE 3. Red blood cells (RBC) count (A) and hemoglobin (Hb) concentration (B) in mice blood. Bars (mean ± SD) having the same letter are not significantly different (Duncan, $p > 0.05$)

The hepatocyte diameter in the CCl₄ group was the widest at $46.25 \pm 6.72 \mu\text{m}$ (Figure 4), in comparison with the other treatments ($p < 0.05$). This result is similar to the study of Ho et al. (2012), in which the hepatocytes were ballooned due to macrovesicular steatosis. In the silymarin and *E. scaber* extract treatment groups, there

was a decrease in hepatocyte diameter compared to the CCl₄ group. The *E. scaber* extract at a concentration of 800 mg/kg had more significant difference in hepatocyte diameter ($28.67 \pm 5.18 \mu\text{m}$) in comparison with the distilled water control group ($27.27 \pm 3.16 \mu\text{m}$). Thus, *E. scaber* extracts showed the ability to restore damaged hepatocytes.

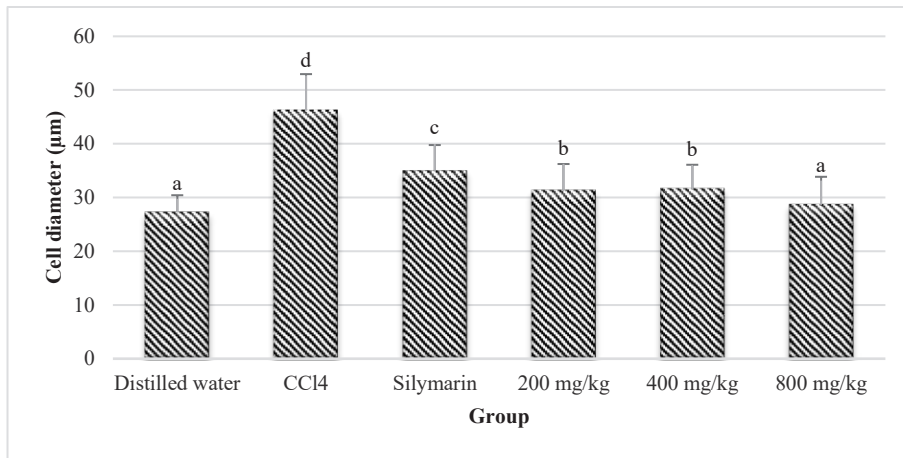


FIGURE 4. Diameter of mouse hepatocytes under the effects of CCl₄, silymarin and *E. scaber* extracts

THE HISTOPATHOLOGY OF MOUSE LIVER

The histology of the mouse liver is shown in Figure 5. Liver sections of normal control mice showed normal

hepatic cells with well-preserved cytoplasm, prominent nuclei, and well brought-out central veins (Figure 5(A), 5(A')). Meanwhile, CCl₄ induced centrilobular necrosis,

which spread to the hepatic cells surrounding the central vein. It also caused extensive infiltration of lymphocytes and Kupffer cells, and necrosis with the loss of nuclei. The presence of small foci of necrotic cells and the occurrence of steatosis or accumulation of fatty droplets were detected in many regions of the liver sections of CCl_4 treated mice.

In this study, the large cells surrounding the necrotic zone are ballooned hepatocytes that might be due to macrovesicular steatosis. Their enlarged cytoplasm led to cell membrane between the cells to stick together, causing unidentifiable capillary spokes (Figure 5(B), 5(B')). This result is consistent with previous studies of CCl_4 effects on the liver by Athokpam, Bawari and Choudhury (2017), Kang and Koppula (2014), and Singhal and Gupta (2012).

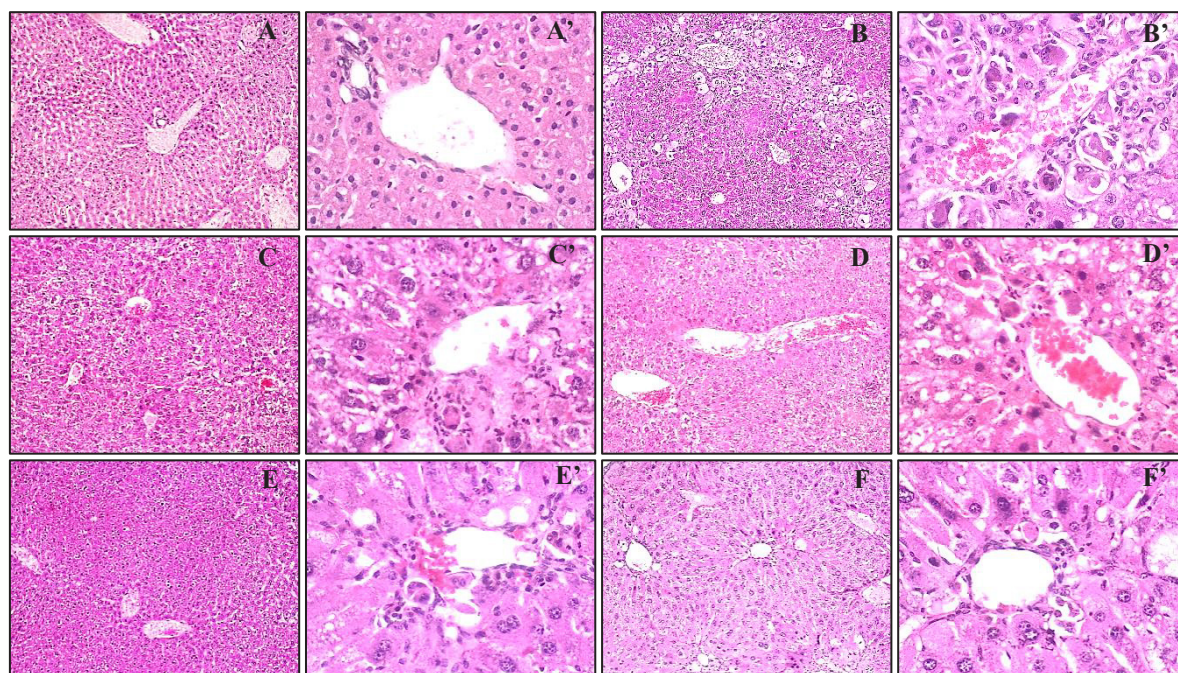


FIGURE 5. The histopathology of mice liver. A, A': distilled water group; B, B': CCl_4 group; C, C': CCl_4 +silymarin group; D, D': CCl_4 +*E. scaber* extract (200 mg/kg) group; E, E': CCl_4 +*E. scaber* extract (400 mg/kg) group; F, F': CCl_4 +*E. scaber* extract (800 mg/kg) group

Mice treated with silymarin after being administered CCl_4 had recovery of liver cells (Figure 5(C), 5(C')). These cells were arranged in series towards the central vein. The phagocytic cells of these tissue were significantly reduced in comparison to those of the CCl_4 treated group. This concentration around vascular structures, which demonstrates the hepatoprotective ability of silymarin, has also been observed in other studies (Athokpam, Bawari & Choudhury 2017; Yang et al. 2019; Zarezade et al. 2018).

Similarly, hepatocytes of mice treated with *E. scaber* extracts (200, 400, and 800 mg/kg) also recovered from CCl_4 damage (Figure 5(D), 5(D'), 5(E), 5(E'), 5(F), 5(F')). This was showed by the reduction of phagocytic

organizations after continuous treatment of these extracts for 14 days. Additionally, the cell enlargement was reduced and the cells were arranged in series, leading to identifiable capillary spokes.

CONCLUSION

We have found that the aqueous extracts of *E. scaber* possess strong biological activities such as antioxidant, antibacterial, and hepatoprotective activity. The flowers and leaves of the *E. scaber* had higher biologically activities than other parts of the plant, so they can be used to prepare essences from this part. Furthermore, the whole plant extracts did not cause any acute toxicity to

experimental mice, even at high concentrations (5000 mg/kg). However, subclinical and clinical follow-up studies are needed to optimize the use of *E. scaber* extracts as a drug.

REFERENCES

- Abdel-Ghany, R.H., Barakat, W.M., Shahat, A.A., Abd-Allah, W.E.S. & Ali, E.A. 2016. *In vitro* and *in vivo* hepatoprotective activity of extracts of aerial parts of *Bidens pilosa* L. (Asteraceae). *Tropical Journal of Pharmaceutical Research* 15(11): 2371-2381. <https://doi.org/10.4314/tjpr.v15i11.11>
- Ahmed Chyad Ali Al Fahad, Zainab Ahmad Hassan, Hadel Sabar Hamad, Mohammed R. Al-Shaheen & Mustafa R. Al-Shaheen. 2018. Determination antimicrobial activity of leaves extracted by various solvents from (*Elephantopus scaber* L.). *IOP Conference Series: Materials Science and Engineering* 454(1). <https://doi.org/10.1088/1757-899X/454/1/012110>
- Al-Manhel, A.J. & Kareem Niamah, A. 2012. Effect of aqueous and alcoholic plant extracts on inhibition of some types of microbes and causing spoilage of food. *Journal of Nutrition & Food Sciences* S5: 006. <https://doi.org/10.4172/2155-9600.S5-006>
- Anitha, V.T., Antonisamy, J.M. & Jeeva, S. 2012. Anti-bacterial studies on *Hemigraphis colorata* (Blume) H.G. Hallier and *Elephantopus scaber* L. *Asian Pacific Journal of Tropical Medicine* 5(1): 52-57. [https://doi.org/10.1016/S1995-7645\(11\)60245-9](https://doi.org/10.1016/S1995-7645(11)60245-9)
- Aquino, R., Morelli, S., Lauro, M.R., Abdo, S., Saija, A. & Tomaino, A. 2001. Phenolic constituents and antioxidant activity of an extract of *Anthurium versicolor* leaves. *Journal of Natural Products* 64(8): 1019-1023. <https://doi.org/10.1021/np0101245>
- Aslam, M.S., Ahmad, M.S., Mamat, A.S., Ahmad, M.Z. & Salam, F. 2016. Antioxidant and wound healing activity of polyherbal fractions of *Clinacanthus nutans* and *Elephantopus scaber*. *Evidence-Based Complementary and Alternative Medicine* 2016: 4685246. <https://doi.org/10.1155/2016/4685246>
- Athokpam, R., Bawari, M. & Choudhury, M.D. 2017. Hepatoprotective activity of aqueous extract of *Oxalis debilis* kunth against CCL₄ - induced liver damage. *Asian Journal of Pharmaceutical and Clinical Research* 10(9): 231. <https://doi.org/10.22159/ajpcr.2017.v10i9.19100>
- Bich, D., Chung, D., Chuong, B., Dong, N., Duong Ton Dam, Hien, P., Lo, V., Mai, P., Man, P. & Dong Nhu. 2006. *Medicinal Plants and Medicinal Animals in Vietnam Vol 1*. Ha Noi: Science and Technics Publishing House.
- Brown, A.C. 2017a. Kidney toxicity related to herbs and dietary supplements: Online table of case reports. Part 3 of 5 series. *Food and Chemical Toxicology* 107(August): 502-519. <https://doi.org/10.1016/j.fct.2016.07.024>
- Brown, A.C. 2017b. Liver toxicity related to herbs and dietary supplements: Online table of case reports. Part 2 of 5 series. *Food and Chemical Toxicology* 107(March): 472-501. <https://doi.org/10.1016/j.fct.2016.07.001>
- Carlin, F. & Nguyen-The. C. 2013. Pathogen update: *Bacillus* species. In *Woodhead Publishing Series in Food Science, Technology and Nutrition: Advances in Microbial Food Safety*. Vol. 1., edited by Sofos, J. Woodhead Publishing Limited. pp. 70-96. <https://doi.org/10.1533/9780857098740.2.70>
- Chaudhari, G.M. & Mahajan, R.T. 2016. *In vitro* hepatoprotective activity of *Terminalia arjuna* stem bark and its flavonoids against CCl₄ induced hepatotoxicity in goat liver slice culture. *Asian Journal of Plant Science and Research* 6(6): 10-17.
- Das, M. & Bandyopadhyay, A. 2017. Biological and chemical sciences promising phytomedicines from *Elephantopus scaber* L: A review. *Research Journal of Pharmaceutical* 6(3): 1508-1518.
- Ho, P.H. 2003. *An Illustrated Flora of Vietnam Vol 2*. Tre' Publishing House.
- Ho, W.Y., Swee, K.Y., Chai, L.H., Raha Abdul Rahim & Noorjahan Banu Alitheen. 2012. Hepatoprotective activity of *Elephantopus scaber* on alcohol-induced liver damage in mice. *Evidence-Based Complementary and Alternative Medicine* 2012: 1-8. <https://doi.org/10.1155/2012/417953>
- Jamali, M.C. 2017. Phytochemical study and *in vitro* antibacterial activity of *Elephantopus scaber* L. *J. Bio Innov.* 6(6): 996-1001.
- Jenny, A., Saha, D., Paul, S., Dutta, M., Uddin, M.Z. & Nath, A.K. 2012. Antibacterial activity of aerial part of extract of *Elephantopus scaber* Linn. *Bulletin of Pharmaceutical Research* 2(1): 38-41.
- Kang, H. & Koppula, S. 2014. Hepatoprotective effect of *Houttuynia cordata* Thunb extract against carbon tetrachloride-induced hepatic damage in mice. *Indian Journal of Pharmaceutical Sciences* 76(4): 267-273.
- Le, K.B. 2007. *Flora of Vietnam (Issue 7)*. Science and Technics Publishing House.
- La, D.M., Tran, M.H., Duong, D.H., Tran, H.T. & Ninh, K.B. 2005. *Plants Resources of Vitenam - Bioactive Plants Vol 1*. Agriculture Publishing House.
- Mandal, S.K., Pal, H., Pal, I., Bose, S. & Roy, B.C. 2019. Biological potential of *Elephantopus scaber* Linn. *Int. J. Pharm. Sci. Rev. Res.* 50(2): 130-134.
- Manssouri, M., Znini, M. & Majidi, L. 2020. Studies on the antioxidant activity of essential oil and various extracts of *Ammodaucus leucotrichus* Coss. & Dur. fruits from Morocco. *Journal of Taibah University for Science* 14(1): 124-130. <https://doi.org/10.1080/16583655.2019.1710394>
- Molyneux, P. 2004. The use of the stable free radical diphenylpicryl-hydrazyl (DPPH) for estimating antioxidant activity. *Songklanakarin Journal of Science and Technology* 26: 211-219. <https://doi.org/10.1287/isre.6.2.144>
- Nithya, P. & Madhavi, C. 2017. Antioxidant activity of 3-arylidene-4-piperidones in the 1,1-diphenyl-2-picrylhydrazyl scavenging assay. *Journal of Taibah University for Science* 11(1): 40-45. <https://doi.org/10.1016/j.jtusci.2014.11.007>

- OECD. 2002. *Test No. 420: Acute Oral Toxicity-Fixed Dose Procedure*. OECD Guideline for Testing of Chemicals, Section 4, Paris: OECD Publishing. <https://doi.org/10.1787/9789264070943-en>.
- Pandian, M., Banu, G. & Kumar, G. 2006. A study of the antimicrobial activity of *Elephantopus scaber*. *Indian Journal of Pharmacology* 38(3): 203-204.
- Parkavi, V., Vignesh, M., Selvakumar, K., Mohamed, J.M. & Ruby, J.J. 2012. Antibacterial activity of aerial parts of *Imperata cylindrica* (L) Beauv. *International Journal of Pharmaceutical Sciences and Drug Research* 4(3): 209-212.
- Pexara, A. & Govaris, A. 2010. *Bacillus cereus*: An important foodborne pathogen. *Journal of the Hellenic Veterinary Medical Society* 61(2): 127-133.
- Pham, H.H. 2003. *An Illustrated Flora of Vietnam (Vol 2). Vol 2*. Ho Chi Minh: Tre' Publishing House.
- Rajesh, M.G. & Latha, M.S. 2001. Hepatoprotection by *Elephantopus scaber* Linn. in CCl₄-induced liver injury. *Indian Journal of Physiology and Pharmacology* 45(4): 481-486.
- Saha, P., Mazumder, U.K., Haldar, P.K., Islam, A. & Suresh Kumar, R.B. 2011. Evaluation of acute and subchronic toxicity of *Lagenaria siceraria* aerial parts. *International Journal of Pharmaceutical Sciences and Research* 2(6): 1507-1512.
- Singhal, K.G. & Gupta, G.D. 2012. Hepatoprotective and antioxidant activity of methanolic extract of flowers of *Nerium oleander* against CCl₄-induced liver injury in rats. *Asian Pacific Journal of Tropical Medicine* 5(9): 677-685.
- Street, R.A., Kulkarni, M.G., Stirk, W.A., Southway, C. & van Staden, J. 2008. Variation in heavy metals and microelements in South African medicinal plants obtained from street markets. *Food Additives & Contaminants: Part A* 25(8): 953-960. <https://doi.org/10.1080/02652030801993605>
- Vo, V.C. 2012. *Dictionary of Medicinal Plants in Vietnam*. Ha Noi: Vietnam Publisher of Medicine.
- Xia, T., Zhang, B., Duan, W., Li, Y., Zhang, J., Song, J., Zheng, Y. & Wang, M. 2019. Hepatoprotective efficacy of Shanxi aged vinegar extract against oxidative damage *in vitro* and *in vivo*. *Journal of Functional Foods* 60: 103448. <https://doi.org/10.1016/j.jff.2019.103448>
- Yang, C.L., Lin, Y.S., Liu, K.F., Peng, W.H. & Hsu, C.M. 2019. Hepatoprotective mechanisms of taxifolin on carbon tetrachloride-induced acute liver injury in mice. *Nutrients* 11(11): 2655. <https://doi.org/10.3390/nu11112655>
- Zaidan, M.R., Noor Rain, A., Badrul, A.R., Adlin, A., Norazah, A. & Zakiah, I. 2005. *In vitro* screening of five local medicinal plants for antibacterial activity using disc diffusion method. *Tropical Biomedicine* 22(2): 165-170.
- Zarezade, V., Moludi, J., Mostafazadeh, M., Mohammadi, M. & Veisi, A. 2018. Antioxidant and hepatoprotective effects of *Artemisia dracunculus* against CCl₄-induced hepatotoxicity in rats. *Avicenna Journal of Phytomedicine* 8(1): 51-62. <https://doi.org/10.22038/ajp.2017.19137.1738>

*Corresponding author; email: nthphuc@ctu.edu.vn